Journal of Antimicrobial Stewardship Practices and Infectious diseases

JASPI

September 2026/Volume 4/Issue 3

Case Report

Carbapenem-Resistant *Pseudocitrobacter Faecalis* Intra-Abdominal Infection in a Patient with Colonic Perforation: A Case Report

Prerna Verma, Anjali Patel, Akshay Arya, Sangram Singh Patel*, Chinmoy Sahu

Department of Microbiology, Sanjay Gandhi Postgraduate Institute of Medical Sciences, Lucknow, India.

* **Corresponding author:** Sangram Singh Patel, Department of Microbiology, Sanjay Gandhi Postgraduate Institute of Medical Sciences, Lucknow, 226014, Uttar Pradesh, India.

Email: sangramsgpgi@gmail.com

Copyright: © Author(s). This is an open-access article distributed under the terms of the Creative Commons Attribution-NonCommercial-NoDerivatives 4.0 International License (CC BY-NC-ND 4.0), which permits non-commercial use, sharing, and reproduction in any medium or format, provided the original author and source are credited, and no modifications or adaptations are made.

ABSTRACT

Pseudocitrobacter faecalis is an uncommon member of the order Enterobacterales, initially described from fecal specimens, and has subsequently been reported from clinically significant infections including bloodstream infections, sepsis and urinary tract infections. Multidrug-resistant and carbapenem-resistant isolates have also been described. However, its clinical significance when repeatedly recovered from intra-abdominal drainage specimens remains uncertain.

A 37-year-old man with no known comorbidities was admitted under the Department of Surgical Gastroenterology with acute moderately severe pancreatitis complicated by colonic perforation. He underwent emergency exploratory laparotomy with diversion loop ileostomy and placement of percutaneous catheter drainage (PCD), followed by surgical drainage. Empirical antimicrobial therapy with meropenem, tigecycline and teicoplanin was initiated. *P. faecalis* was repeatedly isolated as pure growth from PCD/drainage specimens received over a period of approximately five days. The organism was identified by MALDI-TOF mass spectrometry. Antimicrobial susceptibility testing by VITEK 2 demonstrated resistance to amikacin, ceftriaxone, ceftazidime, piperacillin-tazobactam, imipenem, meropenem and minocycline, while colistin was reported as intermediate. The isolate was resistant to ceftazidime-avibactam, whereas qualitative ceftazidime-avibactam–aztreonam synergy testing demonstrated a positive synergistic effect. Despite the susceptibility profile, the empirical antimicrobial regimen was continued, and the patient's clinical condition subsequently improved.

Repeated recovery of multidrug-re faecalis from intra-abdominal PCD/drainage specimens highlights the need to recognize this uncommon organism and carefully assess its clinical significance in patients with gastrointestinal disease. Its multidrug-resistant phenotype and limited in-vitro therapeutic options also emphasize the importance of accurate identification and antimicrobial susceptibility testing of uncommon Enterobacterales isolates.

KEYWORDS: *Pseudocitrobacter faecalis;* Intraabdominal; Antibiotic; Enterobacterales; Hospital Acquired

INTRODUCTION

Pseudocitrobacter faecalis is an uncommon Gram-negative member of the order Enterobacterales. The species was proposed in 2014, when four isolates recovered from stool samples at two military hospitals in Rawalpindi, Pakistan—three of which produced

Citation: Verma P, Patel A, Arya A, et al. Carbapenem-Resistant Pseudocitrobacter Faecalis Intra-Abdominal Infection in a Patient with Colonic Perforation: A Case Report. *JASPI.* 2026;4(3):01-05. DOI: 10.62541/jaspi181

Copyright © Author(s) 2026. JASPI—Journal of Antimicrobial Stewardship Practices and Infectious Diseases.

NDM-1 — were shown by 16S rRNA and multilocus sequence analysis to fall outside Citrobacter, where they had originally been placed on phenotypic grounds.The isolates were subsequently established as a distinct species within the newly proposed genus *Pseudocitrobacter*. Notably, three of the four original isolates were found to produce NDM-1 carbapenemase, highlighting the association of this uncommon organism with clinically important antimicrobial resistance from the time of its initial description.[1]

Although initially identified from fecal specimens, *P. faecalis* has subsequently been recognized in clinical settings. Reports have described its association with bloodstream infection, sepsis and urinary tract infection, and carbapenem-resistant isolates carrying clinically important carbapenemase determinants have been reported.[2-4] A 2021 report described *Pseudocitrobacter anthropi* associated with sepsis and complicated urinary tract infection; subsequent whole-genome taxonomic reassessment established P. anthropi as a later heterotypic synonym of P. faecalis.[2,3] A carbapenem-resistant *P. faecalis* carrying blaOXA-181 was subsequently reported from a bloodstream infection in China, representing the first clinical report of the species outside Pakistan at that time.[4] More recently, P. faecalis has also been reported in a hospital outbreak involving blaNDM-1-producing strains, further emphasizing its potential to acquire and disseminate clinically important antimicrobial resistance.[5]

Despite these reports, the clinical significance of *P. faecalis* in gastrointestinal and intra-abdominal disease remains poorly defined.[2-5] In particular, reports describing its repeated recovery as pure growth from deep intra-abdominal PCD/drainage specimens in patients with gastrointestinal perforation are limited. We report a case of repeated isolation of multidrug-resistant and phenotypically carbapenem-resistant P. faecalis from PCD/drainage specimens in a patient with acute moderately severe pancreatitis complicated by colonic perforation. The case also highlights the diagnostic and therapeutic challenges posed by an uncommon Enterobacterales isolate with limited in-vitro antimicrobial options.

CASE PRESENTATION

A 37-year-old male with no known comorbidities was admitted under the Department of Surgical Gastroenterology, with acute moderately severe pancreatitis complicated by colonic perforation.

The patient underwent emergency exploratory laparotomy on 23 August 2026. Intraoperatively, approximately 500 mL of serous ascitic fluid was evacuated. Adhesions between bowel loops, omentum and parietal structures were noted and adhesiolysis was performed. The bowel was edematous, with a thickened and inflamed mesentery, and interbowel free fluid was present. Fecal contamination was documented as being limited to the retroperitoneum. A diversion loop ileostomy was created and matured in the right iliac fossa.

A percutaneous catheter drainage (PCD) catheter was placed in the left upper paracolic region, from which approximately 100 mL of fluid with feculent content was drained. The PCD was subsequently replaced with a 32-Fr drain. Drainage specimens were submitted to the microbiology laboratory for culture.

The patient was initially started on empirical antimicrobial therapy with meropenem, tigecycline and teicoplanin. PCD/drainage fluid specimens were received in the microbiology laboratory for bacterial culture. On MacConkey agar, medium-sized, circular, glistening lactose-fermenting colonies were observed (Fig.1). On blood agar, the isolate produced circular, grey, non-haemolytic colonies. On Gram staining, thin Gram negative bacilli were seen (Fig.2).

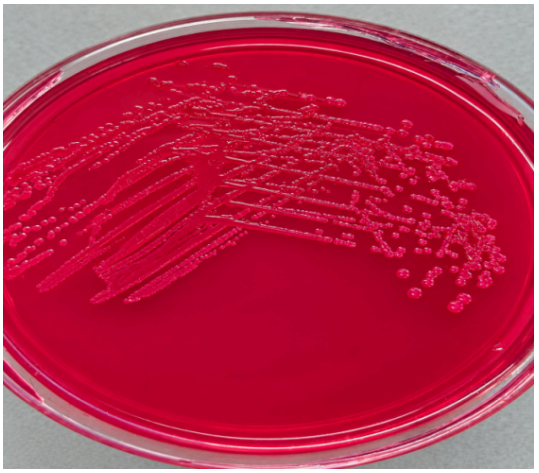

Figure 1. Culture on MacConkey agar showing lactose fermenting colonies

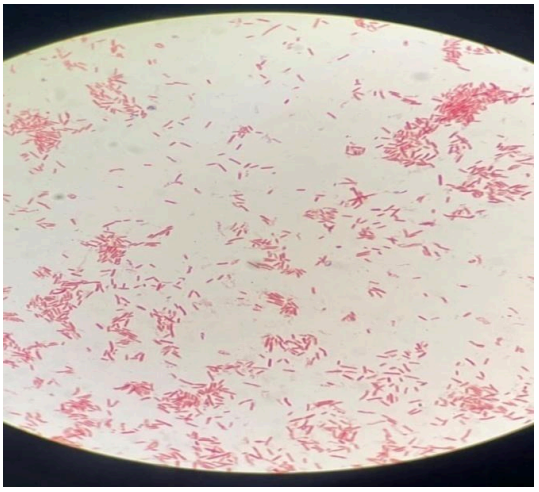

Figure 2. Gram staining showing Gram negative, thin, bacilli

Copyright © Author(s) 2026. JASPI—Journal of Antimicrobial Stewardship Practices and Infectious Diseases.

The isolate was identified as *Pseudocitrobacter faecalis* by MALDI-TOF mass spectrometry. The same organism was repeatedly recovered as pure growth from PCD/drainage specimens received over a period of approximately five days.

Antimicrobial susceptibility testing was performed using the VITEK 2 automated system (bioMérieux). The isolate showed resistance to amikacin (MIC ≥64 µg/mL), ceftriaxone (MIC ≥64 µg/mL), ceftazidime (MIC ≥64 µg/mL), piperacillin-tazobactam (MIC ≥128 µg/mL), imipenem (MIC 4 µg/mL) and meropenem (MIC ≥16 µg/mL), while colistin was reported as intermediate (MIC ≤0.5 µg/mL). (Table 1). Further , tigecycline MIC was found to be 0.25 µg/mL (susceptible) by E-strip method.

Table 1. Antimicrobial susceptibility profile of *Pseudocitrobacter faecalis* isolate by VITEK 2

Antimicrobial	MIC (µg/mL)	Interpretation
Amikacin	≥64	Resistant
Ceftriaxone	≥64	Resistant
Ceftazidime	≥64	Resistant
Piperacillin-tazobactam	≥128	Resistant
Imipenem	4	Resistant
Meropenem	≥16	Resistant
Colistin	≤0.5	Intermediate

Resistance to both imipenem and meropenem indicated a phenotypically carbapenem-resistant isolate. In view of the multidrug-resistant and carbapenem-resistant phenotype, susceptibility to ceftazidime-avibactam (CZA) was further evaluated and the isolate was reported as resistant. A qualitative CZA–aztreonam (ATM) disk approximation/double-disk synergy test was subsequently performed on Mueller-Hinton agar.[6] A CZA disk (30/20 µg) and an aztreonam disk (30 µg) were placed in proximity on the inoculated agar and incubated overnight. Enhancement of the aztreonam inhibition zone toward the CZA disk was observed, indicating a positive synergistic effect between CZA and ATM.

Following the susceptibility results, the empirical antimicrobial regimen of meropenem, tigecycline and teicoplanin was continued by the treating team, as patient was improving and tigecycline was susceptible. After 7 days of treatment, the patient showed clinical improvement and purulent discharge decreased.

Following discharge, he received oral faropenem plus doxycycline were given for 7 days. At follow-up approximately 7 days later, drain output was minimal and the drainage-fluid culture was sterile. So, the drain was removed and antibiotics were stopped.

DISCUSSION

The most notable finding in the present case was the repeated recovery of *Pseudocitrobacter faecalis* as pure growth from PCD and subsequent drain specimens over approximately five days. Although the organism has previously been recovered from fecal specimens and has been associated with clinical infections, reports describing its recovery from deep intra-abdominal drainage specimens are limited.

In the present patient, interpretation of this finding is particularly challenging because of the underlying colonic perforation and feculent intra-abdominal contamination. Repeated recovery from deep specimens makes a single incidental isolation less likely; however, it does not by itself establish *P. faecalis* as the causative pathogen. Translocation from the gastrointestinal tract, persistence within the intra-abdominal collection, or colonization of the drainage system are possible explanations. Therefore, the isolate may be considered potentially clinically significant in the context of the patient's clinical and microbiological findings, while acknowledging that definitive attribution of infection cannot be made from culture results alone.

The antimicrobial susceptibility profile of the isolate adds further significance to the finding. The organism demonstrated resistance to multiple antimicrobial classes, including amikacin, third-generation cephalosporins, piperacillin-tazobactam, imipenem and meropenem, while colistin was reported as intermediate. Resistance to both imipenem and meropenem indicates a phenotypically carbapenem-resistant isolate. Carbapenem resistance has previously been described in *P. faecalis*, including isolates harbouring NDM-1 and OXA-181 carbapenemases.[4,5] However, no molecular characterization or specific carbapenemase detection was performed in the present case. Therefore, the observed resistance phenotype should not be used to infer the presence of a particular carbapenemase mechanism.

An additional finding of interest was resistance to ceftazidime-avibactam (CZA) despite a positive phenotypic interaction between CZA and aztreonam (ATM). The CZA–ATM combination is of particular interest in carbapenem-resistant Enterobacterales because aztreonam is not hydrolysed by metallo-β-lactamases, while avibactam can inhibit co-existing serine *β-lactamases* that may otherwise compromise aztreonam activity.

Copyright © Author(s) 2026. JASPI—Journal of Antimicrobial Stewardship Practices and Infectious Diseases.

In the present isolate, the qualitative disk approximation test demonstrated enhancement of the aztreonam inhibition zone towards the CZA disk, indicating phenotypic synergy. This finding is microbiologically relevant but should be interpreted cautiously. Disk-based synergy methods provide evidence of an interaction between the two agents rather than a quantitative MIC for the combination, and a positive result does not establish the presence of a metallo-β-lactamase or any specific carbapenemase gene in the absence of molecular testing. Moreover, recent comparative studies have shown variable performance among available CZA–ATM synergy methods, with disk approximation showing lower agreement with broth microdilution than some other approaches.[7] Therefore, the result in this case is best described as phenotypic CZA–ATM synergy rather than definitive evidence of a particular resistance mechanism or proof of clinical susceptibility to the combination.

From a clinical perspective, the isolate presented a difficult antimicrobial susceptibility profile as only tigecycline was susceptible. Nevertheless, the treating team continued the empirical regimen of meropenem, tigecycline and teicoplanin, and the patient subsequently improved. This clinical outcome should be interpreted in the context of effective surgical intervention and drainage. The case therefore illustrates an important diagnostic and therapeutic dilemma: an uncommon organism repeatedly recovered from a deep clinical specimen may have potential clinical relevance, while its exact contribution to the disease and the significance of its resistance phenotype may remain difficult to establish.

The current 2026 IDSA AMR guidance recommends that treatment of CRE infections should be based on demonstrated in-vitro activity and, where possible, identification of the carbapenemase mechanism[8]. For invasive CRE infections, treatment options differ according to whether the isolate is non-carbapenemase-producing, KPC-producing, NDM/MBL-producing, or OXA-48-like-producing. The guidance emphasizes susceptibility-guided selection of active agents.

The 2024 IDSA complicated intra-abdominal infection guideline emphasizes appropriate management of complicated intra-abdominal infection and recommends obtaining intra-abdominal cultures in patients undergoing a source-control procedure to guide antimicrobial therapy[9].

Specifically, IDSA recommends obtaining intra-abdominal cultures in adults and children with complicated intra-abdominal infection who undergo source control (conditional recommendation, moderate certainty of evidence). The guideline notes that culture results are particularly useful when patients fail therapy, have recurrent infection, or have uncommon/MDR organisms.

Overall, this case highlights the importance of accurate identification and careful antimicrobial susceptibility testing of uncommon Enterobacterales recovered from deep clinical specimens. In patients with gastrointestinal perforation, repeated recovery of *P. faecalis* should prompt correlation with the clinical setting, specimen depth and quality, repeated culture findings, source control and the organism's antimicrobial susceptibility profile. The multidrug-resistant and phenotypically carbapenem-resistant phenotype observed in this isolate further emphasizes that uncommon Enterobacterales recovered from deep specimens should not be dismissed as contaminants or colonizers without appropriate clinical and microbiological assessment.

CONCLUSIONS

This case highlights the importance of recognizing *Pseudocitrobacter faecalis* when repeatedly recovered from deep clinical specimens, particularly in patients with gastrointestinal pathology. Repeated isolation of the organism, together with its multidrug-resistant and phenotypically carbapenem-resistant profile, warrants careful clinical and microbiological assessment rather than being dismissed as an incidental finding.

ACKNOWLEDGEMENT

None

CONFLICTS OF INTEREST

The authors declare no conflict of interest.

SOURCE OF FUNDING

None

ETHICS STATEMENT INCLUDING PATIENT CONSENT

A well-informed consent was taken from the patient for publication of the case. Ethical approval from the institutional review board was not required for this study.

AUTHOR'S CONTRIBUTION

PV: Conceptualised the case report. Acquired the clinical data and patient history and interpreted the clinical findings. Conducted the literature review and drafted the initial manuscript.

Copyright © Author(s) 2026. JASPI—Journal of Antimicrobial Stewardship Practices and Infectious Diseases.

AP: Collected and compiled the clinical, laboratory and imaging data. Assisted with the literature search and contributed to drafting the manuscript.
AA: Performed and interpreted the laboratory and microbiological investigations. Prepared the figures and tables and revised the manuscript for important intellectual content.
SSP: Conceptualized and supervised the case report. Was involved in the clinical management of the patient and interpreted the clinical and laboratory data. Critically revised the manuscript for important intellectual content.
CS: Supervised the microbiological diagnosis and interpretation of the laboratory findings. Provided expert input on the analysis and discussion and critically revised the manuscript for important intellectual content.
All authors read and approved the final version of the manuscript for publication. All authors agree to be accountable for all aspects of the work, so that questions about the accuracy or integrity of any part of it are appropriately investigated and resolved.

AI DECLARATION

No AI tool was used to generate research data, perform data analysis, interpret findings, formulate scientific conclusions, or make editorial decisions. All AI-assisted content was critically reviewed, verified, and revised by the authors. The authors take full responsibility for the accuracy, originality, integrity, and final content of the manuscript.

REFERENCE

1. Kämpfer P, Glaeser SP, Raza MW, Abbasi SA, Perry JD. *Pseudocitrobacter* gen. nov., a novel genus of the Enterobacteriaceae with two new species *Pseudocitrobacter faecalis* sp. nov., and *Pseudocitrobacter anthropi* sp. nov., isolated from fecal samples from hospitalized patients in Pakistan. Syst Appl Microbiol. 2014;37(1):17-22. doi:10.1016/j.syapm.2013.08.003.
2. Cebollada Sánchez R, Lavilla Fernández MJ, Betrán Escartín A, Ortega Larrea D, Torres Sopena L. *Pseudocitrobacter anthropi* sepsis in a patient with complicated urinary tract infection. Rev Esp Quimioter. 2021;34(3):254-5. doi:10.37201/req/111.2020.
3. Kämpfer P, Fuglsang-Damgaard D, Overballe-Petersen S, Hasman H, Hammerum AM, Fuursted K, et al. Taxonomic reassessment of the genus *Pseudocitrobacter* using whole genome sequencing: *Pseudocitrobacter anthropi* is a later heterotypic synonym of *Pseudocitrobacter faecalis* and description of *Pseudocitrobacter vendiensis* sp. nov. Int J Syst Evol Microbiol. 2020;70(2):1315-20. doi:10.1099/ijsem.0.003918.
4. Shi Q, Guo Y, Yang Y, Wu S, Han R, Ding L, et al. Characterization of the first carbapenem-resistant *Pseudocitrobacter faecalis* harboring blaOXA-181 in China. Antibiotics (Basel). 2022;11(6):737. doi:10.3390/antibiotics11060737.
5. Marano RBM, Oster Y, Benenson S, Motro Y, Ayalon O, Rosenbluh C, et al. An omics-guided investigation of a hospital outbreak caused by blaNDM-1-producing *Pseudocitrobacter faecalis*. J Infect Dis. 2025;232(1):e17-e26. doi:10.1093/infdis/jiaf103.
6. Khan S, Das A, Vashisth D, Mishra A, Vidyarthi AJ, Gupta R, et al. Evaluation of a simple method for testing aztreonam and ceftazidime-avibactam synergy in New Delhi metallo-beta-lactamase producing Enterobacterales. PLoS One. 2024;19(5):e0303753. doi:10.1371/journal.pone.0303753.
7. Bawankar NS, Sayed SEH, Bhise SM, Gaind R. Comparative evaluation of practical in-vitro methods for testing synergy between ceftazidime-avibactam and aztreonam against metallo-β-lactamase and serine carbapenemase-producing Enterobacterales species. Indian J Med Microbiol. 2026;60:101073. doi:10.1016/j.ijmmb.2026.101073. PMID:41638571.
8. Pranita D. Tamma, Samuel L. Aitken, Robert A. Bonomo, Amy J. Mathers, David van Duin, Cornelius J. Clancy. AMR Guidance [Internet]. www.idsociety.org. 2020 [cited 2026 Sept 29]. Available from: https://www.idsociety.org/practice-guideline/amr-guidance/
9. Intra-abdominal Infections [Internet]. www.idsociety.org. [cited 2026 Sept 29]. Available from: https://www.idsociety.org/practice-guideline/intra-abdominal-infections/

Copyright © Author(s) 2026. JASPI—Journal of Antimicrobial Stewardship Practices and Infectious Diseases.