Journal of Antimicrobial Stewardship Practices and Infectious diseases

JASPI

September 2026/Volume 4/Issue 3/Suppl.

JASPI/Pearls/010/2026

Not All Bilateral Exudative Effusions Are Tuberculosis or Heart Failure

Gagan Dalal, Prasan Kumar Panda*

Department of Medicine, All India Institute of Medical Sciences, Rishikesh, Uttarakhand, India.

***Corresponding author:** Prasan Kumar Panda, Department of Medicine (ID Division), All India Institute of Medical Sciences (AIIMS), Rishikesh, 249203, Uttarakhand, India.
Email: motherprasanna@rediffmail.com
Copyright: © Author(s). This is an open-access article distributed under the terms of the Creative Commons Attribution-NonCommercial-NoDerivatives 4.0 International License (CC BY-NC-ND 4.0), which permits non-commercial use, sharing, and reproduction in any medium or format, provided the original author and source are credited, and no modifications or adaptations are made.

CASE VIGNETTE

A 62-year-old female with a background of Hashimoto's thyroiditis presented with 14 days of pleuritic chest pain followed by an acute-onset non-productive cough and progressive exertional dyspnea. Examination revealed reduced air entry and decreased vocal fremitus over the left infra-axillary and infra-scapular regions. Inflammatory markers were markedly elevated (CRP 186 mg/L), with no documented fever.

Chest radiograph showed bilateral pleural effusion (L > R). Pleural fluid analysis revealed an exudative effusion (protein 4.1 g/dL) with mononuclear predominance (80%), low ADA, and sterile microbiology (negative Gram stain, KOH, AFB, CBNAAT, and cultures). Cardiac evaluation (2D-ECHO, CT-CAG, cardiac biomarkers) was unremarkable. HRCT thorax demonstrated fatty proliferation with pericardial thickening, suggestive of a chronic inflammatory process.

The patient showed clinical and radiological improvement with NSAIDs alone, along with a declining CRP trend.

Ques. What is the most likely driver of this patient's bilateral exudative pleural effusion with pericardial thickening?

A. Tuberculous pleurisy

B. Congestive heart failure

C. Acute bacterial mediastinitis

D. Post-viral inflammatory mediastinitis with reactive pleuro-pericarditis

ANSWER: D. Post-viral inflammatory mediastinitis with reactive pleuro-pericarditis.

COMMENTS

This case highlights a non-infectious, inflammatory presentation of mediastinitis with reactive pleural involvement. The alternative diagnoses are less likely for the following reasons:

Option A: Tuberculous pleurisy is unlikely because the pleural fluid had low ADA, sterile microbiology, absence of constitutional symptoms, and showed rapid clinical and radiological improvement with NSAIDs rather than anti-tubercular therapy.

Copyright © Author(s) 2026. JASPI- Journal of Antimicrobial Stewardship Practices and Infectious Diseases.

Option B: Congestive heart failure is improbable as it typically produces transudative pleural effusions and this patient had a clear exudate with lymphocyte predominance and a completely normal cardiac evaluation

Option C: Acute bacterial mediastinitis is unlikely because it usually presents with fever, systemic toxicity, neutrophil-predominant inflammation, and progressive clinical deterioration, none of which were seen, and such cases would not respond to NSAIDs alone..

While bacterial mediastinitis and tuberculous pleurisy are important differentials in endemic settings, the presence of a sterile, lymphocyte-predominant exudative pleural effusion, low ADA, absence of fever, and a marked clinical and radiological response to NSAIDs rather than antibiotics strongly support a post-viral or post-infectious reactive pleural process. Such sterile exudative effusions are well described in post-viral inflammatory states and often resolve with supportive or anti-inflammatory therapy without the need for prolonged antimicrobial treatment.[12]

The HRCT finding of fatty proliferation with pericardial thickening further suggests a subacute inflammatory involvement of mediastinal structures rather than an active infective pathology.

Distinguishing post-viral inflammatory conditions from true infectious aetiologies is a clinically critical step. Infectious pleural effusions — including tuberculous pleurisy — typically demonstrate lymphocyte predominance with elevated ADA, arise in the context of constitutional symptoms (fever, night sweats, weight loss), and do not improve with anti-inflammatory therapy alone. By contrast, post-viral or post-infectious reactive effusions are characterised by sterile cultures, low or normal ADA, temporal association with a preceding viral illness, and prompt resolution with NSAIDs or corticosteroids without any antimicrobial agent. The key distinguishing features in this case — low ADA, sterile microbiology across multiple modalities (Gram stain, KOH, AFB smear, CBNAAT, and cultures), absence of fever, mononuclear-predominant exudate, and rapid NSAID response — collectively and robustly exclude an infectious aetiology.

The decision to withhold both antibiotics and anti-tubercular therapy was reached through careful, stepwise clinical reassessment rather than reflexive empiric treatment. The treating team recognised that initiating anti-tubercular therapy without microbiological confirmation carries a substantial patient burden: a minimum six-month regimen, significant hepatotoxicity risk, potential for drug resistance, and unnecessary patient stigmatisation. Similarly, broad-spectrum antibiotics were not initiated because the clinical picture — haemodynamic stability, absence of systemic sepsis, sterile effusions on comprehensive testing, and a coherent alternative explanation — did not support infection. This case underscores that clinical confidence to withhold antimicrobials, grounded in systematic diagnostic evaluation, is itself an important stewardship act.



Follow-up at 2 weeks: marked resolution of pleural effusion

ANTIMICROBIAL STEWARDSHIP PERSPECTIVE

This case carries important lessons for antimicrobial stewardship, particularly in tuberculosis-endemic regions where the threshold for empiric anti-tubercular therapy is often low. Three stewardship principles are illustrated here. First, avoidance of unnecessary anti-tubercular therapy and antibiotics: the diagnosis was reached through careful synthesis

Copyright © Author(s) 2026. JASPI- Journal of Antimicrobial Stewardship Practices and Infectious Diseases.

of negative microbiological evidence and a supportive clinical narrative, allowing the team to confidently defer antimicrobial treatment. Second, the role of diagnostic stewardship: sequential and appropriate use of ADA measurement, CBNAAT, microbiology cultures (including AFB), and cross-sectional imaging enabled a definitive non-infectious diagnosis without the need for surgical biopsy or empiric therapeutic trials — each test contributed incrementally to narrowing the differential. Third, the importance of clinical reassessment before initiating empiric therapy: rather than committing to treatment based solely on the initial presentation in a high TB-prevalence setting, the team re-evaluated the cumulative diagnostic picture before any antimicrobial was prescribed. This reassessment — integrating effusion characteristics, the inflammatory marker trend, HRCT findings, and the therapeutic response to NSAIDs — was the cornerstone of responsible clinical decision-making and successful stewardship.

REFERENCE

1. Light RW. Pleural effusions. N Engl J Med. 2002;346(25):1971–1977. doi:10.1056/NEJMra020012.https://www.researchgate.net/publication/11300012_Light_RW_Clinical_practice_Pleural_effusion_N_Engl_J_Med_346_1971-1977
2. Sahn SA, Heffner JE. Pleural fluid analysis: the diagnosis of undiagnosed pleural effusions. Clin Chest Med. 2006;27(2):335–350.doi:10.1016/j.ccm.2005.12.007.https://www.24hmb.com/voimages/web_image/upload/file/20140706/14141404655871176.pdf?utm

Copyright © Author(s) 2026. JASPI- Journal of Antimicrobial Stewardship Practices and Infectious Diseases.

Journal of Antimicrobial Stewardship Practices and Infectious diseases

JASPI

September 2026/Volume 4/Issue 3/Suppl.

JASPI/Pearls/011/2026

Erythema Nodosum Leprosum: Inflammatory Fever Mimicking Infection

Mudita Khattri*, Ritu Sangwan

Department of Medicine, All India Institute of Medical Sciences (AIIMS), Rishikesh, Uttarakhand, India.

***Corresponding author:** Mudita Khattri, Department of Medicine (ID Division), All India Institute of Medical Sciences (AIIMS), Rishikesh, 249203, Uttarakhand, India.
Email: khattrimudi@gmail.com
Copyright: © Author(s). This is an open-access article distributed under the terms of the Creative Commons Attribution-NonCommercial-NoDerivatives 4.0 International License (CC BY-NC-ND 4.0), which permits non-commercial use, sharing, and reproduction in any medium or format, provided the original author and source are credited, and no modifications or adaptations are made.

CASE VIGNETTE

A 43-year-old male, farmer with no known comorbidities, presented with history of **recurrent fever for one year** and **painful nodular skin lesions over bilateral upper limb and trunk for 2.5 years**, progressively increasing in number. Examination revealed **tender erythematous nodules** and **thickened peripheral nerves, including bilateral ulnar and greater auricular nerves**. Laboratory evaluation showed markedly elevated ESR, while blood culture and other microbiological work-up returned negative. **Slit-skin smear demonstrated acid-fast bacilli (5+)**, and skin biopsy done was consistent with **erythema nodosum leprosum (ENL)**. Empirical antibiotics which were started were stopped. Diagnosis of **lepromatous leprosy with type 2 lepra reaction** was considered, and the patient improved with **systemic corticosteroids and multidrug therapy (MDT)**.

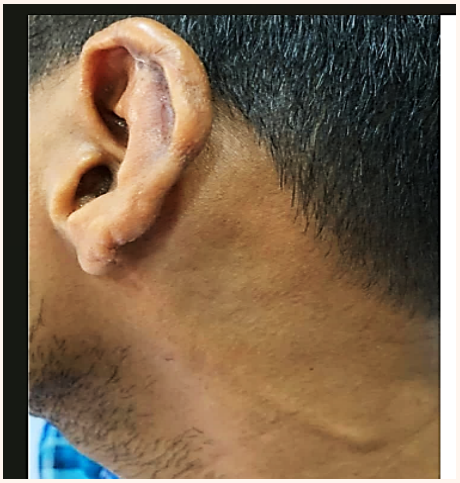

Figure 1: Thickening of Greater Auricular Nerve

Ques. In this patient of leprosy presenting with recurrent fever and tender erythematous nodules, which of the following best explains the mechanism responsible for his fever?

A. Delayed hypersensitivity reaction due to enhanced cell mediated immunity

B. Immune complex mediated inflammatory response related to high bacillary load

C. Secondary bacterial infection due to impaired skin barrier

D. Cytokine release following rapid bacillary killing after multidrug therapy

ANSWER: B. Immune complex mediated inflammatory response related to high bacillary load

COMMENTS

Erythema nodosum leprosum (ENL) is a type III hypersensitivity reaction which is the most frequent manifestation of

Copyright © Author(s) 2026. JASPI—Journal of Antimicrobial Stewardship Practices and Infectious Diseases.

type II lepra reaction. It is seen in lepromatous or borderline lepromatous leprosy. ENL affects about 50% of patients with lepromatous leprosy (LL) and 10% of borderline lepromatous (BL) patients [1]. The risk factors for ENL include Lepromatous Leprosy and a high-bacillary index. Pathogenesis involves systemic inflammatory state driven by immune dysregulation driven by elevated pro- inflammatory cytokines particularly TNF- alpha and IL-1 along with increased levels of INF-Gamma, IL-6, IL-8 and IL-10. Neutrophilic infiltration is the histological hallmark with increased CD4+/ CD8+ ratio [2]. Patient may not report history of leprosy, as it can occur after completion of MDT, or they may be unaware of it. The treatment involves use of immunosuppressant with corticosteroids and thalidomide.

Thus, the appearance of fever, tender nodules and systemic features mimic an infectious process, misinterpreting as sepsis.

REFERENCE

1. Pocaterra L, Jain S, Reddy R, Muzaffarullah S, Torres O, Suneetha S, et al. CLINICAL COURSE OF ERYTHEMA NODOSUM LEPROSUM: AN 11-YEAR COHORT STUDY IN HYDERABAD, INDIA. American Journal of Tropical Medicine and Hygiene [Internet]. 2006 May 1;74(5):868–79. https://pubmed.ncbi.nlm.nih.gov/16687695/
2. Polycarpou A, Walker SL, Lockwood DNJ. A Systematic review of immunological studies of Erythema nodosum leprosum. Frontiers in Immunology [Internet]. 2017 Mar 13;8:233. https://pubmed.ncbi.nlm.nih.gov/28348555/

ISSN: 3048-4510 (Online)
DOI: 10.62541/jaspi0102026

Copyright © Author(s) 2026. JASPI- Journal of Antimicrobial Stewardship Practices and Infectious Diseases.

Journal of Antimicrobial Stewardship Practices and Infectious diseases

JASPI

September 2026/Volume 4/Issue 3/Suppl.

JASPI/Pearls/012/2026

Infective Cause of Spontaneous Pneumothorax

*Monika Saran, Rajshekhar Lohar**

Department of Medicine, All India Institute of Medical Sciences (AIIMS), Rishikesh, Uttarakhand, India.

***Corresponding author:** Mudita Khattri, Department of Medicine (ID Division), All India Institute of Medical Sciences (AIIMS), Rishikesh, 249203, Uttarakhand, India.
Email: dr.rajshekharlohar@gmail.com
Copyright: © Author(s). This is an open-access article distributed under the terms of the Creative Commons Attribution-NonCommercial-NoDerivatives 4.0 International License (CC BY-NC-ND 4.0), which permits non-commercial use, sharing, and reproduction in any medium or format, provided the original author and source are credited, and no modifications or adaptations are made.

CASE VIGNETTE

A 42-year-old sweeper from Northern India presented with progressive dyspnea for the past 3 weeks. One month prior this presentation, he had a 5-day history of fever with chills and a 4-day history of productive cough with yellowish sputum. He was treated empirically with amoxicillin-clavulanate and doxycycline, which led to a reduction in fever intensity. His medical history was significant for recently diagnosed diabetes mellitus (HbA1c: 11.5%). He is a non-smoker but chews tobacco and consumes alcohol socially. 15 days into the illness, the patient sought medical attention at a private hospital for increased dyspnea, where a chest X-ray was performed. An intercostal chest drain (ICD) was inserted, and haemorrhagic pleural fluid was drained. He was treated with cefpodoxime and a respiratory fluoroquinolone. Subsequently, the patient left against medical advice, the ICD was removed, and he was later presented to our hospital. Chest x-ray (figure 1) showed hydropneumothorax and frank pus was aspirated.

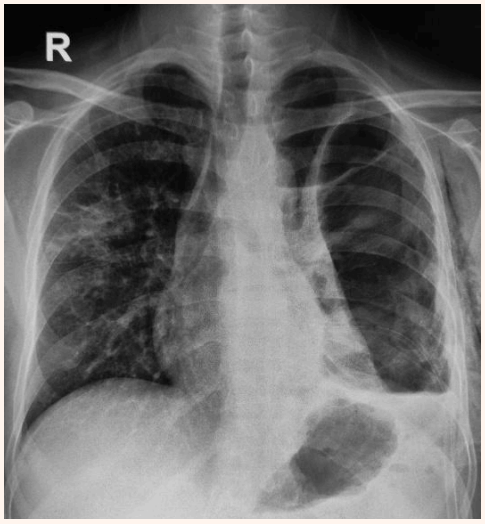

Figure 1: Chest x-ray done at our centre

Ques. Which of the following option(s) is/are true regarding the etiology?

A. Staphylococcus aureus pneumonia

B. Tubercular pleural effusion with complications

C. Pneumocystis jirovecii pneumonia

D. Adenocarcinoma of lung

E. All of the above

Table 1: Relevant preliminary investigations of the patient

Investigations	Reference range	Patient's value
Haemoglobin (g/dL)	12.0 – 15.0	9.4
Total Leucocyte Count (×10³/µL)	4.0 - 11.0	13.13
Neutrophils (%)	40 - 70	84.4
Platelets (×10³/µL)	150 - 400	481

Copyright © Author(s) 2026. JASPI—Journal of Antimicrobial Stewardship Practices and Infectious Diseases.

Serum Creatinine (mg/dL)	0.6 - 1.2	0.78
SGPT (U/L)	0 - 35	67
SGOT (U/L)	0 - 35	59
Serum albumin (mg/dL)	3.5 – 5.2	2.2
CRPH (mg/L)	0 - 1	195
ESR (mm/hr)	< 30	45
Anti-HIV Antibodies	Non-reactive	Non-reactive

ANSWER: B. Tubercular pleural effusion with complications

COMMENTS

This is a case of a middle-aged male with uncontrolled diabetes mellitus who presented with a left-sided spontaneous hydropneumothorax. Routine investigations (Table 1) and focused diagnostic tests were performed. The patient was started on empirical broad-spectrum antimicrobials along with antitubercular therapy (ATT), which was later modified based on culture sensitivity reports. An ICD was placed for management of the hydropneumothorax. Sputum analysis including Gram stain, Ziehl-Neelsen stain, KOH mount, and cytology for atypical cells—was non-contributory. However, both pleural fluid and sputum samples tested positive for *Mycobacterium tuberculosis* on cartridge-based nucleic acid amplification test. Other pleural fluid investigations were inconclusive, except for pleural fluid culture, which showed growth of *Staphylococcus epidermidis* (Table 2), the significance of which was considered in the clinical context. Incidental findings of Pott's spine involving the dorsal vertebrae were noted on a lateral chest X-ray and managed conservatively. The patient showed symptomatic improvement during the hospital stay and was discharged with a diagnosis of disseminated tuberculosis on ATT and ICD in situ. On follow-up visits, the patient showed resolution of the hydropneumothorax; the ICD was removed, and ATT was continued for six months.

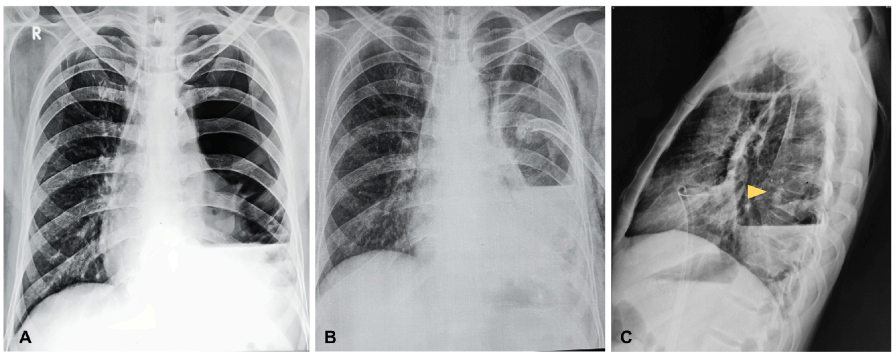

Figure 2: 2a, the first chest x-ray showing air-fluid level in left hemithorax (outside); 2b, chest x-ray taken after ICD insertion (outside); 2c, lateral chest x-ray showing Pott's spine (yellow arrow head)

Antibiotics	Susceptibility
Erythromycin	S
Clindamycin	S
Oxacillin	S
Cefoxitin	S
Tetracycline	S
TMP/SMX	S
Vancomycin	S
Penicillin	R
Linezolid	S

Table 2: Antibiotic sensitivity pattern of *Staphylococcus epidermidis* isolated from pleural fluid culture.

Hydropneumothorax is defined as the presence of both air and fluid within the pleural cavity, typically forming an air-fluid level visible on imaging studies. It can arise from traumatic events or spontaneously, often secondary to infections or malignancies (adenocarcinoma, malignant pleural mesothelioma, and metastasis). The pathogenesis involves parenchymal necrosis and cavity formation within the lung tissue, which may subsequently rupture into the pleural space to form bronchopleural fistula leading to hydropneumothorax.

The patient presented with fever and a productive cough without rusty sputum or haemoptysis, progressing over a subacute course suggest an infection caused by an indolent organism. The subsequent development of dyspnea, which worsened prior to medical evaluation, is indicative of a spontaneous hydropneumothorax (Figure 2). Bacteria such as *Staphylococcus aureus*, *Streptococcus pneumoniae*, *Klebsiella pneumoniae*, and *Mycoplasma pneumoniae* are known for causing fulminant infections. In contrast, infections due to *Mycobacterium tuberculosis*, fungal organisms, and malignancies typically follow a more indolent course. In India, tuberculosis is a predominant cause of

Copyright © Author(s) 2026. JASPI- Journal of Antimicrobial Stewardship Practices and Infectious Diseases.

hydropneumothorax, accounting for approximately 80.7% of cases.[1] Uncontrolled diabetes and occupational exposure predispose him to infections such as tuberculosis and fungal diseases, both of which can lead to hydropneumothorax. Diabetes mellitus impairs immune function, increasing susceptibility to infections, while certain occupations may involve exposure to environmental pathogens. Serological testing for human immunodeficiency virus was negative, reducing the possibility of *pneumocystis jirovecii* pneumonia (PCP). However, PCP can occasionally present with big pulmonary bullae which can rupture into the pleural cavity.[2] Given the absence of risk factors for malignancy, the likelihood of this is reduced.

Diagnosis	Points in favour	Points against
Tuberculous empyema	Endemic in India Chronic course of the illness (fever and cough) Haemorrhagic pleural fluid Diabetes is a risk factor Hydropneumothorax can result from ruptured TB cavity	Lack of constitutional symptoms (weight loss, night sweats)
Bacterial empyema (post-pneumonic)	History of productive cough □ haemorrhagic pleural fluid can occur in severe infections. Diabetes increases risk of severe pulmonary infections.	Initial antibiotic therapy may have partially treated infection, leading to atypical presentation. Usually fulminant course without antibiotic therapy.
Parapneumonic effusion complicated by bronchopleural fistula	History suggestive of pneumonia□ development of hydropneumothorax suggests air leak. Presence of frank pus indicates empyema	No direct evidence of fistula
Fungal empyema (Aspergillus, Candida)	Diabetes as a significant risk factor Chronic course of the illness Poor response to antibiotics Haemorrhagic pleural fluid can be seen in fungal infections	Fungal empyema is rare
Malignancy related effusion (Lung cancer, metastasis)	Haemorrhagic pleural effusion Age group at risk for malignancy	No history of smoking or asbestosis exposure No weight loss or other systemic symptoms No mass lesions reported on imaging

REFERENCES

1. Kasargod V, Awad NT. Clinical profile, etiology, and management of hydropneumothorax: An Indian experience. Lung India. 2016 May 1;33(3):278-80. https://pubmed.ncbi.nlm.nih.gov/27185991/
2. Davies P, Bradley C. Vanishing lung syndrome: giant bullous emphysema. The Lancet. 2017 Dec 9;390(10112):2583. https://pubmed.ncbi.nlm.nih.gov/28965716/

ISSN: 3048-4510 (Online)
DOI: 10.62541/jaspi0102026

Copyright © Author(s) 2026. JASPI- Journal of Antimicrobial Stewardship Practices and Infectious Diseases.

Journal of Antimicrobial Stewardship Practices and Infectious diseases

JASPI

September 2026/Volume 4/Issue 3/Suppl.

JASPI/Pearls/013/2026

The Quiet Invader: Chronic Pulmonary Aspergillosis — Think Beyond the Cavity

Mudita Khattri, Prasan Kumar Panda*

Department of Medicine, All India Institute of Medical Sciences (AIIMS), Rishikesh, Uttarakhand, India.

***Corresponding author:** Prasan Kumar Panda, Department of Medicine (ID Division), All India Institute of Medical Sciences (AIIMS), Rishikesh, 249203, Uttarakhand, India.
Email: khattrimudi@gmail.com
Copyright: © Author(s). This is an open-access article distributed under the terms of the Creative Commons Attribution-NonCommercial-NoDerivatives 4.0 International License (CC BY-NC-ND 4.0), which permits non-commercial use, sharing, and reproduction in any medium or format, provided the original author and source are credited, and no modifications or adaptations are made.

CASE VIGNETTE

A 41-year-old man with a one-month history of fever, progressive painless skin ulcers over both upper and lower limbs (Fig 1A), with a past history of pulmonary tuberculosis (2016) for which he completed 6 months of anti-tubercular therapy, and a history of rheumatic heart disease. Echocardiography revealed a large calcified mitral valve vegetation (22×16 mm2). An extensive work-up was performed, which included repeated blood cultures, autoimmune serology (ANCA, ANA), and a skin biopsy, which were negative for any organism or vasculitis. CECT thorax showed a fibro-cavitary lesion with an air-crescent sign in the right upper lobe (Fig 1B), while the Aspergillus-specific IgG was ,markedly elevated at 48.20 (reference range < 27 mgA/L). Over the course of the hospital stay, the vegetation spontaneously decreased in size (22×16 mm2 to 8×13 mm2), and the skin ulcers healed without antibiotic or antifungal treatment. . There was subsequent massive hemoptysis, which ultimately required lung resection; histopathology confirmed Aspergillus species.

Figure 1: Skin ulcer (A) and CT findings of chronic cavitary pulmonary aspergillosis (B)



1 (A)



2 (B)

Ques. Which of the following steps would be most suitable to help make a diagnosis of chronic cavitary pulmonary aspergillosis (CCPA)?

A. CT-guided lung biopsy for histopathological confirmation of fungal hyphae

B. Serum Aspergillus-specific IgG

C. Bronchoscopy with bronchoalveolar lavage (BAL) galactomannan

D. Empirical antifungal therapy with voriconazole to see treatment response

Copyright © Author(s) 2026. JASPI—Journal of Antimicrobial Stewardship Practices and Infectious Diseases.

ANSWER: B Serum Aspergillus-specific IgG

COMMENTS

Chronic pulmonary aspergillosis (CPA) is a well-known, but under-diagnosed, complication in about 26% of patients with treated pulmonary tuberculosis (TB) with residual post-TB cavities[1]. Unlike in case of invasive pulmonary aspergillosis (IPA), CPA occurs in immunocompetent hosts and is characterized by chronic local Aspergillus colonisation driving a host IgG response (rather than dissemination). This is why serum galactomannan (a marker of invasive disease) and blood/sputum cultures are usually negative in CPA and should not be used to rule out the diagnosis[1]. Diagnostic cornerstone is Aspergillus-specific IgG combined with computed-tomography (CT) findings (air-crescent sign / fibrocavitary changes consistent with chronic cavitary pulmonary aspergillosis, CCPA) in a patient with underlying structural lung disease. The ERS 2016 guidelines define CPA by this triad —Compatible clinical symptoms for more than or equal to 3 months, radiological feature and microbiological or serological evidence of Aspergillus[1]. The antifungal therapy is initiated based on the elevated Aspergillus specific IgG and compatible CT findings alone without waiting for histopathological confirmation. The lung resection performed in this case, following a massive hemoptysis and subsequent histopathological confirmation of Aspergillus, was a mere incidental finding, not a diagnostic necessity. Although CPA/CCPA is generally regarded as a localized pulmonary infection, persistent exposure to Aspergillus antigens may result in chronic immune activation, autoantibody production, and, rarely, secondary immune-mediated manifestations, including eosinophilic granulomatosis with polyangiitis via allergic bronchopulmonary aspergillosis[2]. In the absence of fungal invasion on skin or valvular histopathology, extrapulmonary manifestations may therefore represent immune dysregulation rather than hematogenous dissemination of the fungus.

In our case, spontaneous resolution of a sterile mitral valve vegetation and healing of the skin lesions without antimicrobial treatment gives rise to the interesting question of whether chronic exposure to Aspergillus antigens leads to immune complex formation (significant levels of IgG), which causes a sterile multisystem inflammatory process that predisposes to sterile vegetation of the mitral valve and sterile skin lesions. Non- invasive, immune-mediated process, thus cannot be captured with galactomannan and cultures.

The most important stewardship lesson is: in any post- TB patient with persistent pulmonary symptoms or unexplained systemic inflammation, a high index of suspicion for CPA/CCPA should be considered, supported by Aspergillus -specific IgG testing; this avoids unnecessary ATT or broad-spectrum antibiotics, and prevents misdiagnosis as TB relapse[3].

Histopathological confirmation can establish CPA/CCPA, but it is invasive and not routinely required to establish the diagnosis when the clinical picture, CT findings, and Aspergillus-specific IgG are strongly supportive. Histology becomes particularly useful when the diagnosis remains uncertain, malignancy or another pathology needs exclusion, or tissue is being obtained for another clinical indication. BAL galactomannan can detect Aspergillus antigen in the respiratory tract and has an important role in IPA, particularly in appropriate high-risk hosts. However, its diagnostic performance and role are less established for CPA/CCPA than Aspergillus-specific IgG[2]. Also, a positive BAL galactomannan does not by itself distinguish chronic Aspergillus disease from airway colonization. Similarly, respiratory fungal culture can provide microbiological evidence and may be useful for species identification and susceptibility testing, particularly when treatment is planned or resistance is suspected[2]. However, Aspergillus isolation from respiratory samples can represent colonization, and culture has limited sensitivity. Therefore, a negative culture does not exclude CPA/CCPA, while a positive culture alone does not establish it.

REFERENCE

1. Page ID, Byanyima R, Hosmane S, Onyachi N, Opira C, Richardson M, et al. Chronic pulmonary aspergillosis commonly complicates treated pulmonary tuberculosis with residual cavitation. European Respiratory Journal. 2019 Jan 31;53(3):1801184. Available from: https://doi.org/10.1183/13993003.01184-2018
2. Denning DW, Cadranel J, Beigelman-Aubry C, Ader F, Chakrabarti A, Blot S, et al. Chronic pulmonary aspergillosis: rationale and clinical guidelines for diagnosis and management. European Respiratory Journal. 2015 Dec 23;47(1):45–68. Available from: https://doi.org/10.1183/13993003.00583-2015

Copyright © Author(s) 2026. JASPI- Journal of Antimicrobial Stewardship Practices and Infectious Diseases.

3. Huisamen T, Thomson H, Harrington KRV, Baines N, Ackermann C, Griffith-Richards S, et al. A retrospective study exploring chronic pulmonary aspergillosis in post-tuberculosis lung disease patients. Journal of Thoracic Disease. 2025 Jan 1;17(1):320–32. Available from: https://doi.org/10.21037/jtd-24-106

Copyright © Author(s) 2026. JASPI- Journal of Antimicrobial Stewardship Practices and Infectious Diseases.